

Case Report

J Ped. Nephrology 2014;2(2):83-86
<http://journals.sbm.ac.ir/jpn>

Giant Hydronephrosis Due to Congenital Uretropelvic Junction Obstruction, a Report of 2 cases

How to Cite This Article: Sadeghi-Bojd S, Fazeli F, Keshavarz K, Baktash M. Giant Hydronephrosis Due to Congenital Uretropelvic Junction Obstruction, a Report of 2 cases. J Ped. Nephrology 2014;2(2):83-86.

Simin Sadeghi-Bojd,¹
Faramarz Fazeli,¹
Kambiz Keshavarz,²
Maryam Baktash¹

1Children and Adolescent R Center,
Zahedan University of Medical Sciences,
Zahedan, Iran.

2Pediatrician, Social Determinants of
Health Research Center. Yasuj University
of Medical Sciences, Yasuj, Iran

*Corresponding Author

Kambiz Keshavarz, MD
Pediatrician, Social Determinants of
Health Research Center. University of
Medical Sciences, Yasuj, Iran
kmbz_ped86@yahoo.com

Received: Feb-2014

Revised: Mar-2014

Accepted: Mar-2014

Ureteropelvic junction (UPJ) stenosis occurs in 13% of children. Antenatally, the diagnosis is possible by showing renal pelvis dilatation by obstetric ultrasonography. Giant hydronephrosis (GH) is a rare condition. There are different etiologies for GH which are mostly congenital and occur during infancy and childhood. GH was confirmed by complementary evaluations in a 2-month-old female infant with poor feeding, lethargy, and vomiting together with an antenatal sonography in favor of hydronephrosis, and a 5-year-old boy with an abdominal mass diagnosed by sonography following 2 weeks of progressive abdominal distention. Pyeloplasty was associated with an excellent result in both of them.

Keywords: Hydronephrosis; Ureteral Obstruction; Congenital; Urologic Diseases.

Running Title: Giant Hydronephrosis Due to Congenital UPJO

Introduction

Urinary tract obstruction is a relatively common problem in the pediatric age group. The obstruction of urinary flow may occur at any site of urinary tract and may be acute or chronic, partial or complete, and unilateral or bilateral. The major causes of urinary tract obstruction are different based of the age of the patients. Anatomic abnormalities (including urethral valves or stricture, and stenosis at the ureterovesical or ureteropelvic junction) account for the majority of the cases in children. In comparison, calculi are the most common cause in young adults while prostatic hypertrophy or carcinoma, retroperitoneal or pelvic neoplasms, and calculi are primary causes in older patients [1,2]. Giant

hydronephrosis is a rare entity. Approximately 200 cases of GH have been reported [3]. The presence of more than 1 liter of urine in the urinary collecting system is defined as GH. It is also defined as a kidney occupying more than half of the abdomen, meeting or crossing the midline, and with at least five vertebral bodies in length [4]. The most common cause of giant hydronephrosis is congenital ureteropelvic obstruction followed by stones, trauma, and tumors. The clinical features of giant hydronephrosis may include asymptomatic long standing gradual painless distension of the abdomen [5]. Affected patients may also present with flank pain, backache, hematuria following trivial trauma and shock [6]. Approximately, two

thirds of these kidneys can preserve their renal function, and are also amenable to repair [4]. It can mimic many acute and chronic abdominal conditions like acute peritonitis, ovarian cyst, and tumors, retroperitoneal hematoma, hepatobiliary cyst, pancreatic pseudocyst, mesenteric cyst, pseudomyxoma, renal tumors and cysts, adrenal cysts, retroperitoneal tumors, splenomegaly, and massive ascites when it occupies the whole abdomen [7,8,9,10]. Establishing the correct diagnosis of giant hydronephrosis is necessary to plan management. The classic ultrasound features of giant hydronephrosis are many large multiseptal cystic lesions communicating with each other [7]. Congenital giant hydronephrosis due to ureteropelvic junction is exceptional and treatment often requires nephrectomy of the poorly functioning kidney [4]. When hydronephrosis is massive, preoperative renal function assessment is difficult because the collecting system is extremely dilated and the renal parenchyma is very thin. Thus, nephrectomy is often considered instead of pyeloplasty in these cases [11]. We report 2 cases of giant hydronephrosis with 1000 cc and 1500 cc retained urine in their urinary tract, respectively. Both of them were primarily diagnosed as an abdominal mass.

Case Report

Case 1

A 2-month-old female infant with an antenatal sonography in favor of right side hydronephrosis was referred to us because of anuria, poor feeding, and repeated vomiting. A large mass was palpable on abdominal physical examination. Renal ultrasonography and abdominal CT scan demonstrated a 128×116 mm large cyst containing about 1000 cc fluid (Figure 1). Voiding cystourethrogram (VCUG) was normal but radionuclide dynamic renogram (99Tc DTPA) revealed a dilated renal pelvis due to lower obstruction without any excretion on the right side. The results of urinalysis, urine culture, serum electrolytes, BUN, and creatinine were normal. Open surgery was done and further evaluations confirmed huge hydronephrosis (a very enlarged renal pelvis) secondary to UPJO. At last, pyeloplasty was performed for the patient with an excellent result.

Case 2

A 5-year-old boy was hospitalized because of progressive abdominal distention (suspicious

ascites) and abdominal pain from 2 weeks ago. Physical examination and abdominopelvic sonography revealed a large hypoechoic mass lesion occupying nearly the whole abdomen and pelvic cavity with multiple septated internal echoes. Blood urea, creatinine, and hemoglobin were 13 mg/dl, 0.6 mg/dl, and 9 g/dl, respectively. Blood sugar and serum electrolytes were within the normal limits. Urine analysis did not reveal any abnormalities and urine culture was negative. Based on renal ultrasonography, the parenchyma and size of the right kidney were normal but pelvic fullness was noted. The size of the left kidney was reported 107×55 mm with grade III hydronephrosis. 99Tc DTPA scintigraphy demonstrated GFR equal to 45% in the left and no excretion was noted during dynamic renogram. He underwent left kidney pyeloplasty and the left renal pelvis was reduced (Figure 2). After surgery, the function of the kidneys returned to normal.

Discussion

Giant hydronephrosis secondary to UPJO is a rare childhood condition. It is more often seen in males than in females, especially on the left side (60%). In our report, the first case was a female infant with giant hydronephrosis on the right side and the second case was a boy with GH on the left side. Based on the available reports, sex predominance is variable. Sataa S reported a female to male ratio of 3:2 [12,19]. The amount of fluid in the hydronephrotic sac is often between 1 and 2 liters. In one study, 268 ml urine was drained from the left kidney of a 39-week newborn by percutaneous nephrostomy [15]. Giant hydronephrosis is usually secondary to UPJO, stone formation, or congenital urinary tract abnormalities. Crooks K et al. studied twenty pediatric patients with giant hydronephrosis. The majority of them [16] were cases with UPJO (5). Giant hydronephrosis may present with vague symptoms such as nausea, fatigue or dyspepsia, urinary tract infection [19,21], renal insufficiency [20], gross hematuria after trauma especially in adults, duodenal obstruction [16], and malrotation [15], massive ascites [10], abdominal mass [2,8] and acute abdomen [19,7]. However, patients usually remain asymptomatic until the late stages, because this situation usually progresses slowly.

Monika reported a 5-year-old boy who presented with progressively increasing abdominal distension since birth with no associated urinary or gastrointestinal symptoms [14]. Giant hydronephrosis seldom fills the entire abdomen and differentiation between such a condition from ascites may then be difficult on clinical examination alone. For example, the second case of our report was diagnosed at the age of 5 years and was hospitalized because of suspicious ascites. Since the majority of the cases of UTO can be corrected by proper surgery and a delay in therapy can lead to irreversible renal injury, early diagnosis is very important [20]. Radiologic evaluations are generally used to differentiate UTO from similar conditions. These modalities are also used for the detection of the level of obstruction in the urinary system. Abdominopelvic ultrasonography is the modality of choice for excluding UTO. Avoiding the potential allergic and toxic complications of radiocontrast media is the advantage of this method. Similar to Saata, WT Yang recommended ultrasound as a quick and sensitive method for establishing the diagnosis [12,19] but in many cases, differentiation between giant hydronephrosis and other cystic formations is difficult. Prenatal ultrasonography of our first case demonstrated right side hydronephrosis. In the second case, although late, ultrasonography helped us to follow the patient correctly. Despite these facts about ultrasonography, replacing other modalities such as excretory, ante or retro-grade urography, and CT scan is a challenge for diagnosis in some patients [11,12]. The essential aim of the treatment of giant hydronephrosis should be preservation of the kidney. Further treatment depends upon the function of the affected kidney. Nephrectomy is often performed due to severe impairment of the renal function [17,2]. Crooks et al. found it necessary to remove the kidney in only 30% of the cases [18]. In the study performed by Sataa S et al., the nephrectomy rate was 33% and they recommended nephrectomy in a kidney participating in less than 20% of the total renal function and renal parenchymal thickness <5 mm [12]. Monika et al and Crooks et al. reported that

most of the patients require nephrectomy [4,14]. Reconstructive surgery like pyeloplasty is performed in young children with a salvageable renal function and those with a bilateral disease [22,23]. In a study by Harper JD et al., all of the patients underwent laparoscopic nephrectomy (LN) and laparoscopic nephroureterectomy (LNU) for severe hydronephrosis and it was found that five of them had giant hydronephrosis in a non functioning kidney. Therefore, our cases underwent unilateral kidney pyeloplasty and after surgery, the function of kidneys was normal. In conclusion, since most of the cases can be treated and delay in therapy can lead to irreversible renal injury, early diagnosis of UTO is important. Also, careful follow-up is necessary for the detection of renal stone, urinary tract infection, and other susceptibilities. We suggest complementary evaluations in each person with abnormal or suspicious antenatal sonography.

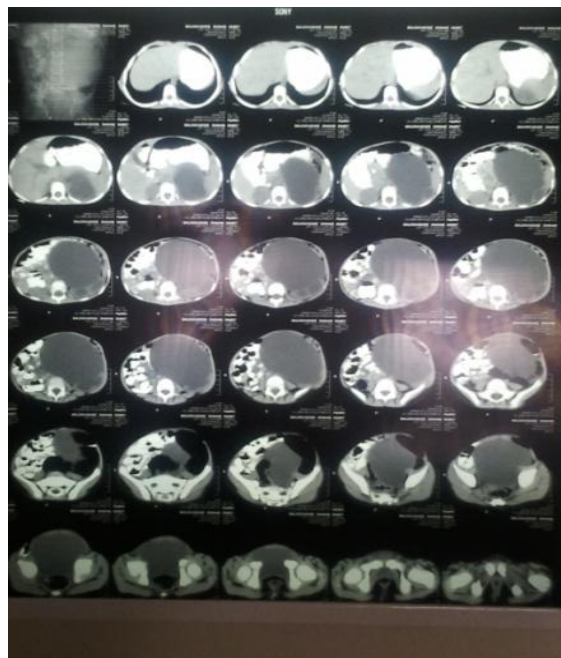


Figure 1 Abdominal CT scan showing giant hydronephrosis with pressure effect over the bowels (case 1)

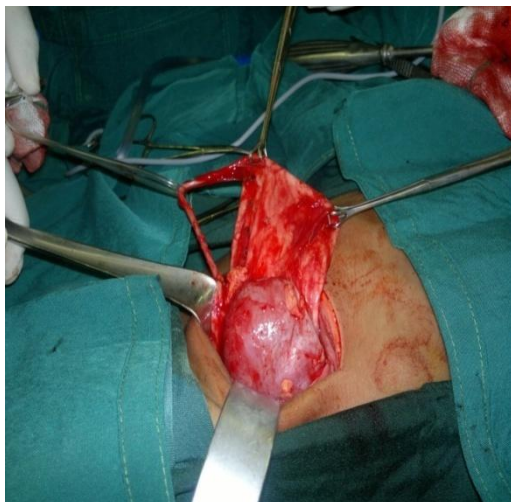

Figure 2 Intraoperative picture of giant hydronephrosis (case 2)

Acknowledgement

Authors Contribution:

Study concept and design: Dr. Sadeghi-bojdSimin, Dr. Fazeli Faramarz

Analysis and interpretation of data: Dr.Sadeghi-bojdSimin

Drafting of the manuscript: Dr. Baktash Maryam

Critical revision of the manuscript for important intellectual content: Dr. keshavarz Kambiz

Statistical analysis: Dr. Sadeghi-bojdSimin

Conflict of Interest

None declared

Financial Support

None declared

References

1. Armando J. Lorenzo, Dagmar Csaicsich, Christoph Aufricht, and Antoine E. Khoury "Obstructive Genitourinary Disorders" In: Geary, Denis F, Schaefer, Franz. "Pediatric nephrology". Lippincott Williams & Wilkins 2011. P. 561-68.
2. Debnath J, Roy R, Kumar S, Pandit A. Congenital Giant Hydronephrosis: A rare cause of upper abdominal mass in the newborn ;J Clin Neonatol 2013;2(1):33–35.
3. Earlam MS: Giant Hydronephrosis. J Urol 1950;63:195.
4. Crooks KK, Hendren WH, Pfister RC; Giant hydronephrosis in children. J. Pediatr. Surg 1979;14:844-50.
5. Chiang PH, Chen MT, Chou YH, Chiang CP, Huang CH, Chien CH. Giant hydronephrosis: report of 4 cases

- with review of the literature. J. Formos. Med. Assoc. 1990;89:811-17.
6. Shanmugasundaram Rajaian, MCH, Nitin Sudhakar, MS ,DNB. Giant hydronephrosis mimicking massive ascites. ANZ journal of surgery 2012;468-469.
7. Grover CA, Crisp JG; Giant hydronephrosis presenting as an acute abdomen. Br. Med. J. 1964;1: 1229-30.
8. Schrader AJ, Anderer G, von Knobloch R, Heidenreich A, Hofmann R. Giant hydronephrosis mimicking progressive malignancy. BMC Urol. 2003;3:4.1-4
9. Mountney J, Chapple CR, Johnson AG. Giant hydronephrosis a diagnostic dilemma. Urol. Int. 1998;61:121-3.
10. Singh NK, Jha B, Khanna R, Khanna NN; Giant hydronephrosis masquerading as massive ascites. postgrad. Med. J. 1993;69:800-2.
11. Yilmaz E, Guney S. Giant hydronephrosis due to ureteropelvic junction obstruction in a child: CT and MR appearances. Clin Imaging. 2002;26(2):125-8.
12. Sataa S, Kerim C, Sami BR, Nizar D, Rochdi E, Nidhameddine E, et al. Giant hydronephrosis in adult: What is the best approach? Retrospective analysis of 24 cases. Nephro-Urol Mon. 2011;3(3):177-181.
13. Shaikh NA, Sheikhbir GS, Larik A. Giant Hydronephrosis Professional Med J 2012;19(4): 546-548.
14. Bawa M, Mahalik s Rao N. Giant hydronephrosis: uncommon presentation of a common disease; Arch Dis Child 2012;97:525.
15. Abhyankar AB, Strong D, Kothari M, Chapman S, Parahar K. 5:case reports, Giant hydronephrosis: a pitfall in the diagnosis of malrotation. BJU International 2000;86(9):1093
16. Uzzo RG, Poppas DP, Schuman RW, Vaughan ED Jr; An unusual cause of duodenal obstruction: ureteropelvic junction obstruction and the relationship; Urology. 1994;44(3):433-6.
17. Benhaddou H, Bellahcen M, Elazzouzi D; Giant hydronephrosis in a child (a new case report); Arch Pediatr. 2013;20(10):1126-8.
18. Harper JD, Shah SK, Baldwin DD, Moorhead JD; Laparoscopic nephrectomy for pediatric giant hydronephrosis. Urology. 2007;70(1):153-6.
19. WT Yang, C Metrewel: Diagnostic dilemmas: Giant hydronephrosis in adults: the great mimic .Early diagnosis with ultrasound Post grad Med J 1995;71: 409-412.
20. Masanori Yamamoto, Hatsuki Hatsuki, Koji :A Case of unilateral Giant Hydronephrosis With renal insufficiency : Nagoya J. Med. Sci. 1995;58:107-110,
21. Sepulveda, b, Filipe Rodrigues: Giant Hydronephrosis - A Late Diagnosis of Ureteropelvic Junction, World J Nephrol Urol 2013;2(1):33-35.
22. Nerli, R. B. Reddy, M. N. Hiremath, M. B. Shishir, D. Patil, S. M. Guntaka, A. Surgical outcomes of laparoscopic dismembered pyeloplasty in children with giant hydronephrosis secondary to ureteropelvic junction obstruction: J Pediatr Urol 2012;8(4):401-4.
23. Kalfa, N. Lopez, C. Baud, C. Veyrac, C. Morin, D. Averous, M. Congenital giant hydronephrosis: long-term results of primary neonatal nephroplication: Prog Uro 2006;16(4):481-4.